

INTRODUCTION

Head and Neck Squamous Cell Carcinoma is usually treated with Radiation Therapy (RT). Image registration is important to combine the information obtained by different image modalities and to correct the shift between the pre and post-treatment images. A comparison of the tumor size and texture in the pre- and post-treatment images gives a measure of the effectiveness of the treatment.

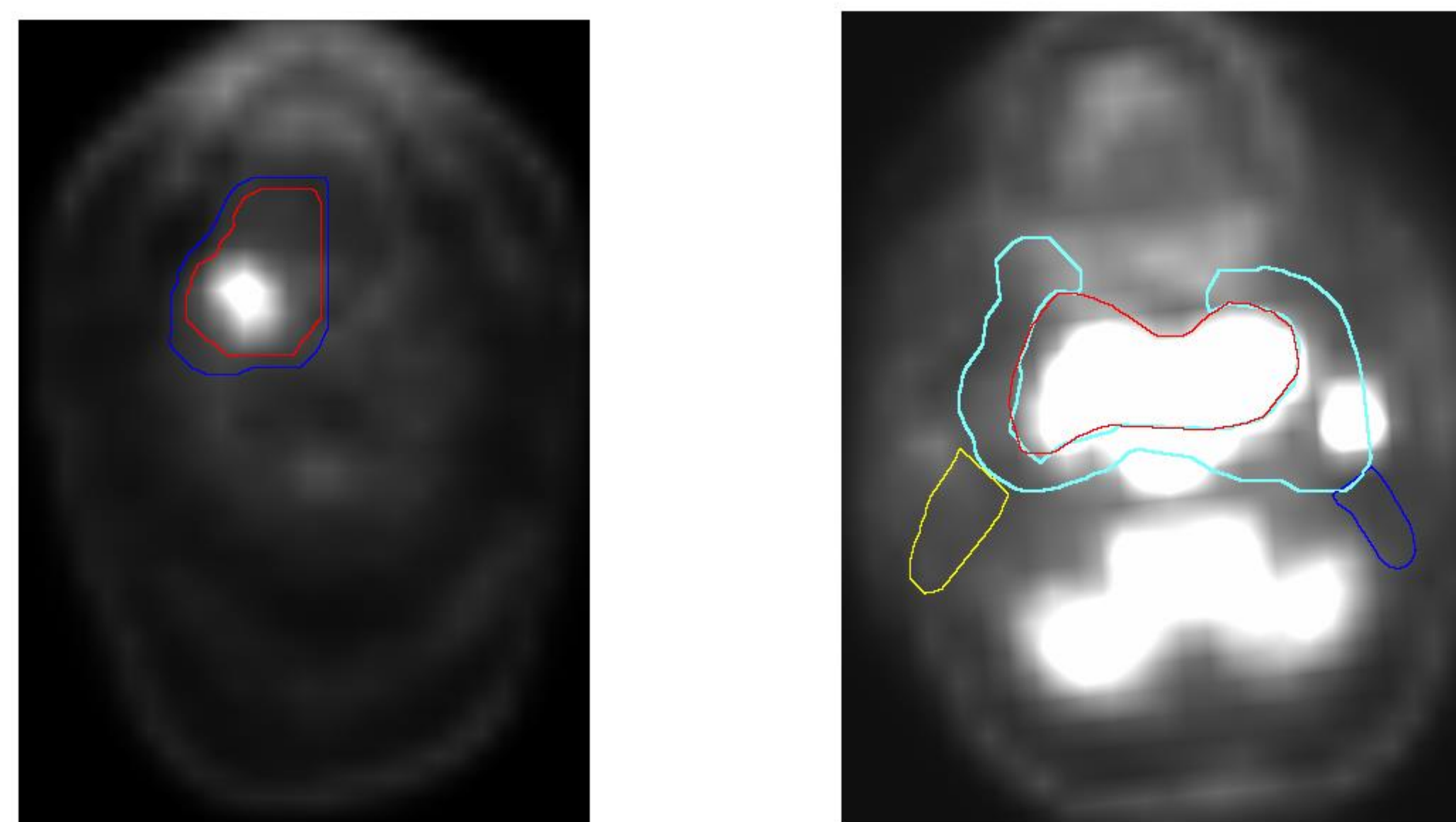



Fig: RT Structure indicating the position of the tumor in the baseline PET images

TUMOR DETECTION AND EXTRACTION

1. Patients who have had a local recurrence of the tumor are identified.
2. Control group for each patient includes patients who are in the same age group and have the same tumor site.
3. RT Structure is overlain on the pre-treatment PET image to identify the tumor regions.
4. The bright region in the PET image indicates the tumor region as it has maximum FDG uptake.



(a)

(b)

Figures (a) and (b) show the tumor region marked in the PET image and the region as extracted from the original image. The different colors in the tumor boundary signify the different RT dose.

FEATURE EXTRACTION FOR 2D TEXTURE ANALYSIS

Patients are divided into two categories : Local Recurrent and Non Local Recurrent, on the basis of whether they have had a local recurrence of the tumor after treatment or not. 6 patients are included in the first category and 14 patients in the second.

The following four texture measures are calculated for each image slice of these 20 patients:


1. Laws
2. GLCM
3. Fourier
4. Hu's Moments

3D TEXTURE ANALYSIS

Original PET Slices are viewed in the RadiAnt DICOM Viewer and compared with the slices from the RT workstation to identify the original slices which have been indicated to have the tumor. The tumor region is then extracted using the RT structure boundaries. This region is then converted to a 3D volume.

FEATURE EXTRACTION FOR 3D TEXTURE ANALYSIS

The following four types of texture measures were calculated for slice:
 GLCM, GLRLM, GLSZM, NGTDM



The figures show the tumor region marked in the PET image and the corresponding original PET slice as viewed in RadiAnt

CLASSIFICATION RESULT

For 2D texture analysis:

Best classification accuracy- 84.5%

Classifier used- RusBoosted Trees

Confusion matrix result:

Local recurrence- 66% correct classification

Non local recurrence- 89% correct classification

For 3D texture analysis:

Best classification accuracy- 79.2%

Classifier used- Quadratic SVM

Confusion matrix result:

Local recurrence- 50% correct classification

Non local recurrence- 82% correct classification

CONCLUSION

Registration of images of different modalities is important to obtain structural and physiological information about the tumor regions. The RT data help to identify the tumor boundaries and indicate the radiation dose when overlain on the PT images. We believe that tumor texture characteristics[3][4] will help us in our comparative study of the patients with and without the local recurrence of the tumor.

ACKNOWLEDGEMENTS

This project is supported by a grant from the GW Cross-Disciplinary Research Fund.

REFERENCES

- [1] J. Hill, Derek LG, et al. "Medical image registration." *Physics in medicine and biology* 46.3 (2001): R1.
- [2] Bay, Herbert, Tinne Tuytelaars, and Luc Van Gool. "Surf: Speeded up robust features." In *European conference on computer vision*, pp. 404-417. Springer, Berlin, Heidelberg, 2006.
- [3] Raju, Jisy, and C. Anand Deva Durai. "A survey on texture classification techniques." *Information Communication and Embedded Systems (ICICES), 2013 International Conference on*. IEEE, 2013.
- [4] Satyanarayana, C. H., and S. Anuradha. "A Review of Recent Texture Classification: Methods."

IMAGE DATABASE

1. The database is a new entry in the TCIA(The Cancer Imaging Archive).
2. Diagnostic scans in the form of DICOM images are included for 215 patients.
3. The modalities included are CT,PET,MR,RT.
4. Clinical data include 71 attributes including sex, age and site of the tumor.

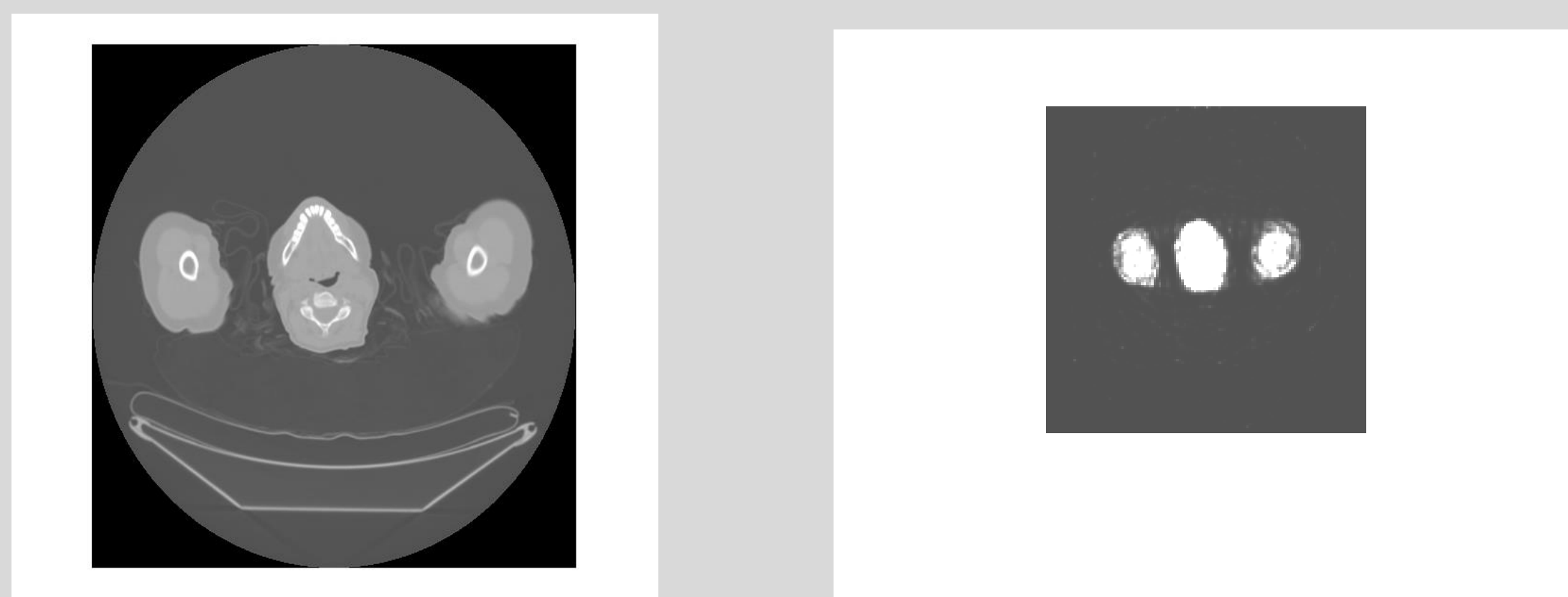


Fig: Corresponding baseline (pre-treatment) CT and PET images.